

Tushar Sharma, MD  
UNIVERSITY OF NEBRASKA MEDICAL CENTER  
Omaha

[tushar.sharma0@gmail.com](mailto:tushar.sharma0@gmail.com)

(716) 400-4779

Original research (includes database studies and QI projects)

**Title:** Utility Of Routine 45-day Imaging After Watchman Procedure Before Stopping Anticoagulation

**Description:** Even though transesophageal echocardiogram (TEE) is routinely performed at 45 days after WATCHMAN implantation to rule out device-related thrombus (DRT) or peri-device leak (PDL) before oral anticoagulation (OAC) is stopped, the risk of stopping anticoagulation without imaging is low. Providers can stop anticoagulation with reasonable confidence at 45 days in cases where TEE is not possible.

### Background:

Based on the PROTECT AF and PREVAIL trials, transesophageal echocardiogram (TEE) is typically performed 45 days after WATCHMAN (Boston Scientific, DE) implantation to rule out device-related thrombus (DRT) or peri-device leak (PDL) before stopping oral anticoagulation (OAC). The utility of imaging before discontinuing OAC is uncertain. During the COVID-19 pandemic, when elective TEEs were cancelled or delayed, many patients were taken off OAC without imaging.

### Methods:

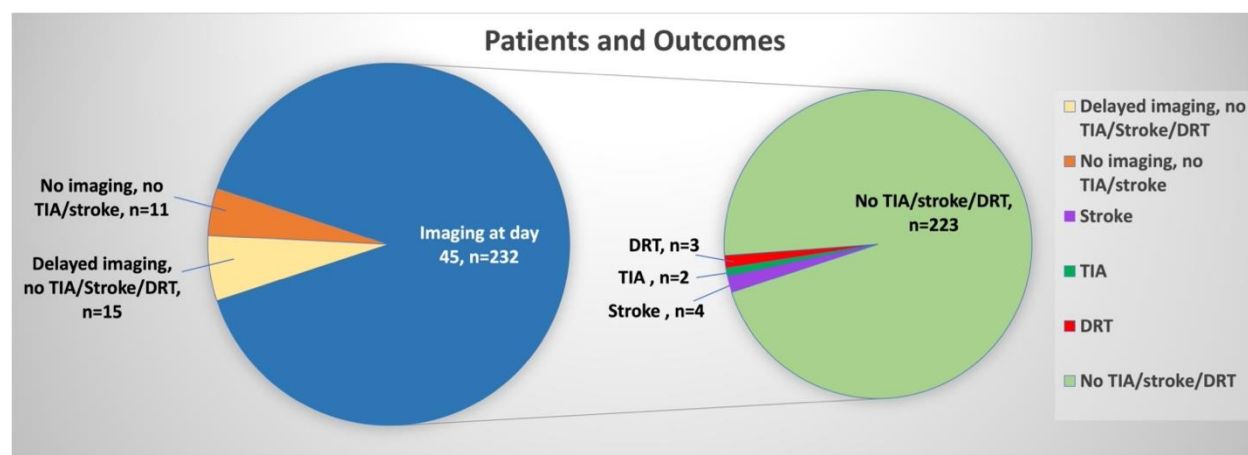
Patients undergoing WATCHMAN implant followed by short-term OAC from January 2018 to June 2022 at a university hospital were analyzed retrospectively. Patients who did not have imaging performed at 45 days (+/-7 days) after WATCHMAN implantation were compared with those who did. Outcomes included 1) a composite of ischemic stroke and transient ischemic attack (TIA), 2) a composite of DRT or PDL  $\geq 5$  mm in patients who had 45-day imaging, and 3) a composite of DRT or PDL  $\geq 5$  mm in patients who were taken off OAC at 45 days without imaging but underwent delayed imaging (within 1 year of WATCHMAN implantation).

### Results:

258 patients were followed for 1 year. 232 patients (89.9%) had TEE or cardiac computed tomography (CT) at 45 days (Figure). 3 had DRT (1.3%), which was treated successfully with 90 days of anticoagulation, and none had PDL  $\geq 5$  mm. There were 4 ischemic strokes and 2 TIAs during the follow up period (2.6%), none of which were preceded by DRT. 26 patients (10.1%) were taken off OAC at 45 days without imaging. No stroke or TIA occurred in this group. No DRT or PDL  $\geq 5$  mm was seen in the 15 of these 26 (58%) patients who underwent delayed imaging.

### Conclusion:

A primary strategy of 45-day post-WATCHMAN imaging is still indicated, given a  $\sim 1\%$  DRT rate, however the risk associated with discontinuing anticoagulation without imaging is low in cases where 45-day imaging is not possible.



## References:

1. Holmes DR, Reddy VY, Turi ZG, et al. Percutaneous closure of the left atrial appendage versus warfarin therapy for prevention of stroke in patients with atrial fibrillation: a randomised non-inferiority trial. *Lancet* 2009;374:534-42.
2. Holmes DR, Jr., Kar S, Price MJ, et al. Prospective randomized evaluation of the Watchman Left Atrial Appendage Closure device in patients with atrial fibrillation versus long-term warfarin therapy: the PREVAIL trial. *J Am Coll Cardiol* 2014;64:1-12.